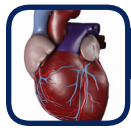

Excerpts from “The Prone Positioning of Patients On Operating Room Equipment: Intra-operative Complication”

By Helen M. Manson MB ChB MRCGP (UK)

Prone Positioning In The OR

The way in which the patient is supported whilst prone influences the occurrence and severity of complications. The design of support equipment to minimize these complications, together with appropriate education of staff in how to optimize the preventive qualities of support devices, is vitally important.

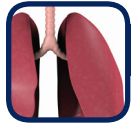

Cardiopulmonary

In the prone posture, **pressure on the abdomen compresses the inferior vena cava (IVC)** and femoral veins, diverting blood from the distal parts of the body into perivertebral venous plexuses. The use of **support surfaces that minimize intra-abdominal pressure**, are recognized as essential in order to reduce the risks of IVC obstruction. Venous drainage can be inadvertently obstructed by **knee or hip flexion, allowing pooling of blood** in the dependent structures and reducing atrial filling and cardiac output.

“The successful outcome of surgery on the thoracic and lumbar spine is largely dependent on the proper positioning of the patient before the operation begins”

Iqbal Singh, M.D, The Prone Position: Surgical Aspects, 1987.



Respiratory

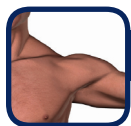The necessary **high airway pressures** and large tidal volumes **needed to ventilate** a patient who is improperly positioned prone can have several potential side effects. Provided that the patient is supported with the **abdomen free from pressure**, prone positioning is known to **improve ventilation/perfusion** matching and consequently improve oxygenation in the surgical patient. If abdominal compression occurs, this can lead to decreased respiratory compliance. Inadvertent compression can happen if the patient is **obese or incorrectly positioned** on the operating frame. Under these circumstances, very high airway pressures may be required to ensure adequate ventilation.



Neurological

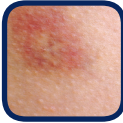It is generally accepted that **careful positioning of the neck**, and head support in a neutral position are **essential to prevent neurological injury** while prone. *CASE:* the use of **chest rolls** led to **increased venous pressure**, which, when combined with mild arterial hypotension, decreased the perfusion pressure in the spinal cord, causing ischemia. *CASE:* a patient who had a **fatal ischemic stroke** after being positioned prone with the head rotated during spinal surgery.

Prone positioning is known to be a high risk factor for patients with **pre-existing** spinal cord dysfunction. *CASE:* reports describe postoperative **paraplegia** due to cervical spine injury, **attributed to neck positioning** during prone spinal surgery. Patient support devices that minimize abdominal compression and maintain the neck and body in a **neutral position can help prevent these neurological complications**.



Nerve

Peripheral nerve injury is one of the **most frequent causes of morbidity** resulting from improper positioning intra-operatively. Compression of the **lateral femoral cutaneous nerve (meralgia paresthetica)** is a common complication of the prone position during spine surgery. Several case reports relating to **nerve injury of the head and neck** have been described in Edgcombe's review, all attributed by the authors to **nerve compression** related to the prone position. It is widely-acknowledged that positioning of the patient is an important causative factor in the occurrence of peripheral nerve damage, and that correct positioning, as well as the use of **support devices** that minimize pressure effects, are **key to the prevention of these injuries**.




Skin

Pressure ulcers that are initiated by surgery often do not appear until one to four days after an operation. It is evident that **prone patients are at risk of pressure ulcer development**, related to the increased risk inherent in undergoing a surgical procedure, the prolonged nature of spinal surgery, and the vigorous manipulation often required in this type of surgery (increasing the likelihood of shearing forces). "Pressure ulcers, regardless of their origin, represent negative outcomes for patients, including pain, additional treatments, and surgery, longer hospital stays, disfigurement or scarring, increased morbidity, and increased costs.

Sanada et al assessed patients undergoing lengthy surgical procedures, measuring skin blood flow using laser Doppler flowmetry (1997) **Pressure ulcers were seen at the iliac bony prominences of all of the patients who underwent spine surgery** in the prone position.

“The mere existence of a pressure ulcer is often viewed as physical evidence of medical negligence. It is widely recognized that intra-operatively acquired pressure ulcers expose nurses, surgeons, anesthesiologists and institutions to significant litigation risk.”

ECRI Institute (2006)



Pressure

Pressure on the trachea can result in serious consequences, since airway problems are difficult to manage in the prone patient and can result in cardiac arrest secondary to hypoxaemia.

Compression of the heart or great vessels has occurred in patients positioned prone during spinal surgery, in cases where there is an anatomical abnormality, such as scoliosis or pectus excavatum and after cardiac surgery. **Flexion of the hips and knees whilst prone can lead to ischemia** of the muscles in the lower limbs, especially if surgery is prolonged.

The process of placing such patients prone, or the application of **prolonged pressure on joints while prone** can lead to joint or bone pain, or bone fractures. The prone position may **inadvertently damage breast tissue**, resulting in chest wall pain, breast tenderness or bleeding of the nipples. Longitudinal positioning frames or rolls can damage breast tissue by direct compression.



Ocular

There is no doubt that **eye complications are associated with the prone position** during anesthesia, and the use of head support equipment. Compared with supine and lateral positioning, there is a ten-fold increase in eye injury associated with surgery while prone. "Ophthalmic complications are well recognized in patients who have been prone under anesthesia, and can be devastating. **Corneal abrasion** is a well-recognized, usually self-limiting, complication of anesthesia, ...resulting from incomplete closure of the eye, drying of the eyes, foreign bodies or other unintended materials contacting the eye during surgery. Biswas et al found an **incidence of 55%** for conjunctival abrasions in prone patients undergoing cranial or spinal surgery in the prone position.

It is known that postoperative visual loss (**POVL**) is associated with spinal surgery and with prone positioning, **67% of all cases of post-operative visual loss** registered on the American Society of Anesthesiologists Postoperative Visual Loss Registry **occurred after prone surgery**. **Direct external pressure on the globes and periorbital structures**, caused by a headrest or other support, is known to increase intraocular pressure, potentially resulting in central retinal artery occlusion and POVL. **CASE:** A silicone head rest was used. The patient experienced facial edema, corneal edema with an extensive corneal abrasion, a nonreactive pupil, advanced cataract and complete ophthalmoplegia, leading to complete and irreversible visual loss in the eye.